

# **Revelations of the Hidden Truth of Charloe Musu’s Murder Story:**

## **Part II- The Philosophy of a Half-Filled Glass**

**By**

**Rockefeller F. Cooper II, MD, Msc., MsP (FDI), F-IACME**

On this 22<sup>nd</sup> day of June 2023, as I put forth a series of unrevealed facts surrounding the death of Charloe Musu as a continuation of my previous article which directly challenged the preliminary autopsy finding by Dr. Benedict Kolee who alluded that Charloe’s CAUSE-of-DEATH was due to a “single” stab wound on the upper left side of her chest (lateral chest) where her left lung was punctured, thus causing her to bleed internally and resulting in her death as reported, I am now in a more comfortable position to speak on Charloe’s behalf and present for the first time ever, hard-core facts that have never before been made public. My level of confidence stems from the fact that additionally, as mentioned in an interview by Dr. Kolee, Charloe’s death was due to excessive “loss of blood” as a result of an injury to the left intercostal artery which also resulted in the *collapse* of her left lung due to the formation of a left thoracic *hemothorax*. Regardless of the versions reported, it is disputable facts like these that make his preliminary report quite nonsensical and highly questionable to a forensically trained mind and soul.

Focusing on the forensic analysis of the mortal remains of the late Charloe Musu and sections of the crime scene at the residence of the Former Chief Justice of the Republic of Liberia, Cllr. Gloria Musu-Scott in addition to the press conference held by some family members on April 6, 2023, as they raised concerns based on their presence during the autopsy, it is my goal as an expert witness and professional in the field of Forensic Medicolegal Death Investigation to accomplish the following:

1. Questioning the possibility that an intruder was responsible for stabbing Charloe to death, based on the wound pattern analysis.

2. Discussing the Bloodstain pattern in sections of the home as a means of providing an insight as to what may have happened, thus creating a path to address a lot of the What? When? Was? Were? Where? Who? And why? that may be in speculation.
3. Enable the Liberian society to have a clear understanding as to what really caused Charloe's death.

As a recall from the FrontPage Africa media outlet, on the 22<sup>nd</sup> of February 2023 between the hours of 9 to 10 PM at the residence of Cllr. Gloria Musu Scott (Former C.J.R.L) located in the Sheriff Gas Station Community in the township of Virginia, district 17, Montserrado County, it was alleged that the said residence was attacked by an alleged armed robber who stabbed the late Charloe Musu, a niece of Justice Scott as well as a promising and expected graduating student from Starz University in Monrovia.

An eyewitness account given by **Mr. Alvin Gezzie** stated that while indoors for the night, he heard neighbors screaming of armed robbers being in the community and thought they had been apprehended, only to find out the robbery was at the former Chief Justice's residence, where they stabbed Charloe to death in the bathroom and then proceeded to Counselor Scott, who fended off the attack by using a "pepper-spray" in self-defense. Moments later, it was in his car that Charloe finally "give up the ghost", as she bled profusely while en route to the hospital.

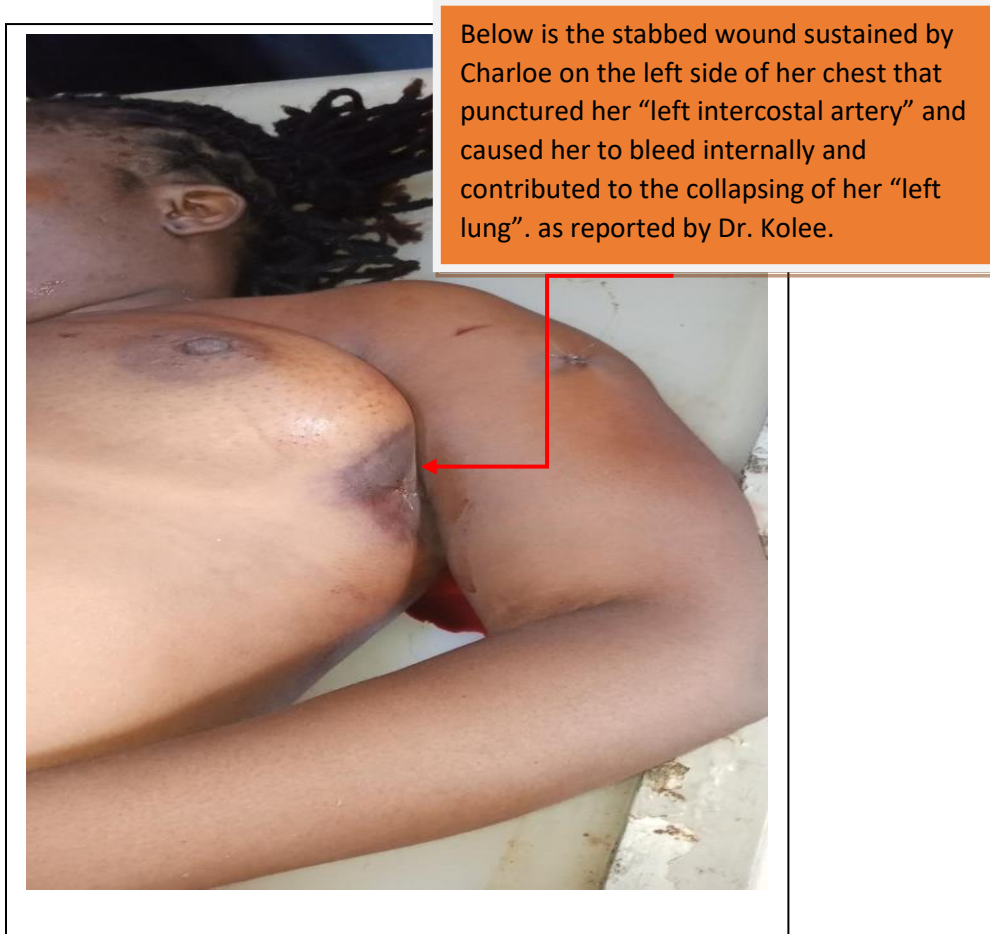Another eyewitness by the name of **Lusine Sheriff** stated that as part of the search party that responded to the said residence to help rescue the occupants and apprehend the robbers, they stumbled upon the gates and doors being locked. The Private security hired by Counselor Scott after two (2) previous robbery attempts as alleged, stated that they could not open the gate for entry since the keys were in the home itself with Counselor Scott, meaning, the gate could only be opened by occupants of the residence. As a result, he and others entered the compound (more than likely by climbing over the fence) and searched the ceiling and the external part of the residence but saw no one [as in an armed robber(s)] and during that time, the occupants were in their respective rooms.

Given the eyewitness accounts above, let us ask ourselves the following:

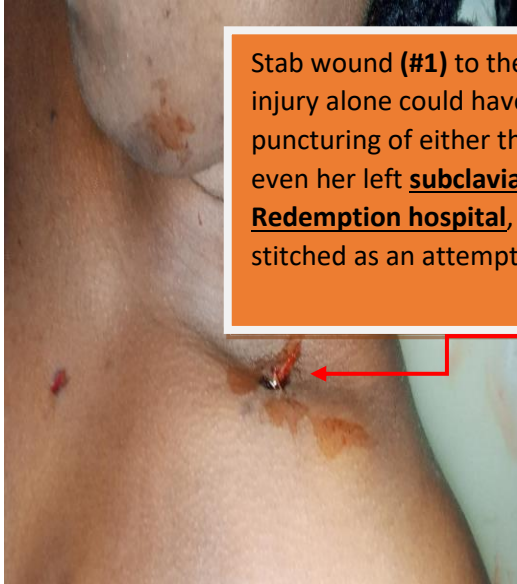
1. Was there any sign of a break-in on the night of February 22, 2023, especially with security on guard?
2. As the gates and doors could only be opened by an occupant of the residence, at what time was the house opened for neighbors to make entry?
3. Who were those that went into the home to check on the well-being of Justice Scott and her family?
4. Who were those that took Charloe to Mr. Gezzie's car and who accompanied him to the hospital?
5. Was Mr. Gezzie's car ever examined by the police?
6. What time did Mr. Gezzie arrive at the Redemption Hospital with Charloe's remains?
7. What time was Charloe pronounced dead by staff at the body at Redemption Hospital?
8. What action was taken by hospital staff on the body, though Charloe was pronounced dead? \*
9. Where did the coroner (Mr. Abraham Ricks) do his initial examination of the deceased?
10. Why did Coroner Ricks turn the body over to the family?
11. Why did St. Moses Funeral Home take instructions from the GOL/MOJ not to allow access to the body which they did not deposit and had no custody of?

**Analysis of Charloe Musu's Body:**

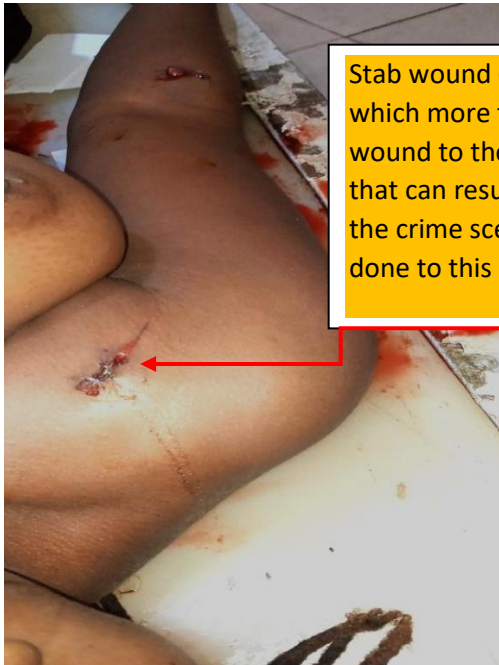- 1.** Below is a picture of the injury to the left side of Charloe's breast which was allocated to her cause of death by Dr. Benedict Kolee in his preliminary report. This is not possible given the fact that:
  - A. She sustained other stab wounds that were more detrimental and deadlier than a stabbing injury which would cause the victim to suffer HEMOTHORAX, a condition that is treatable when taken to the hospital.
  - B. The Bloodstain Pattern Analysis at the crime scene does not support any possibility that Charloe bled out from an injury to her left lung or intercostal artery. If that was the case, then it means that she was being denied medical assistance by fellow occupants of the residence as hemothorax is highly treatable as previously mentioned.



- 2.** Below are stabbed wounds sustained by Charloe which are critical and indeed consistent with Bloodstain patterns at the crime scene since her body was dragged from an exact location in the house to the bathroom.

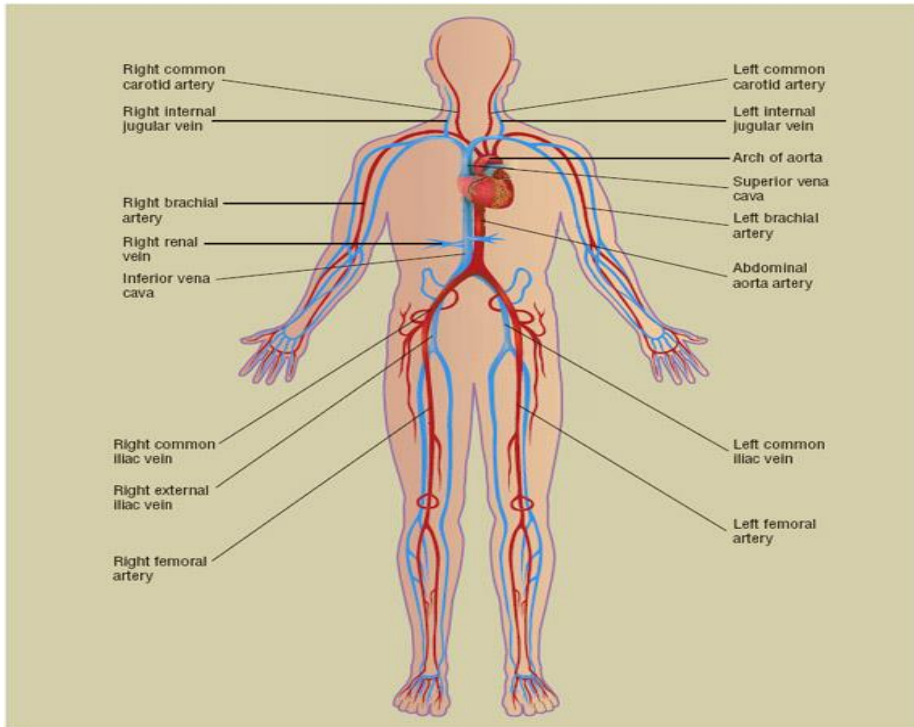


Stab wound (**#1**) to the Left side of the neck and clavicle (collar bone) region. This injury alone could have led to Charloe's death because such an injury could lead to the puncturing of either the carotid artery or jugular vein on the left side of her neck or even her left subclavian artery based on the depth and angle of the stab. At Redemption hospital, or at some point in time, this wound, like others noted, were stitched as an attempt to conceal and stop the bleeding of an already dead Charloe.

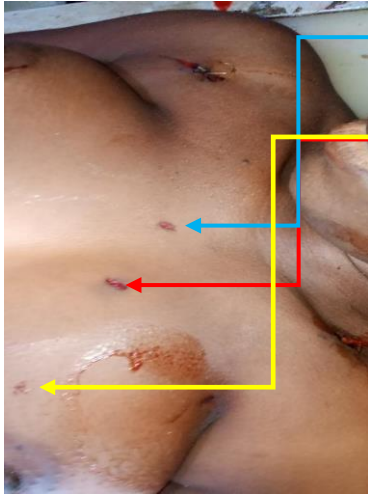


Stab wound (**#2**) to the right upper chest area which more than likely led to a puncture wound to the right subclavian vessel, an injury that can result in severe bleeding as noted at the crime scene. This is why stitches were also done to this wound.

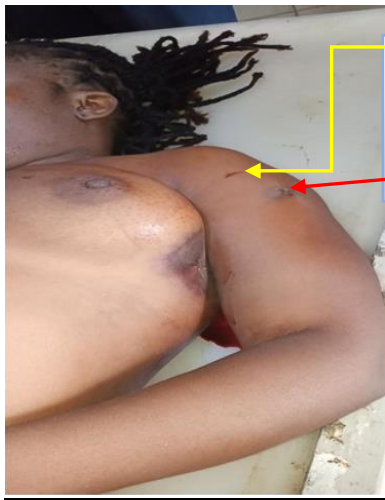- 3.** To understand the importance of the stab wounds discussed above, see the diagram below. These injured vessels are off-springs of the heart and would cause a “bloody” crime scene as the “heart” is pumping, as opposed to a “single” stab chest wound causing an injury, be it to the left lung or intercostal artery as mentioned by Dr. Kolee.



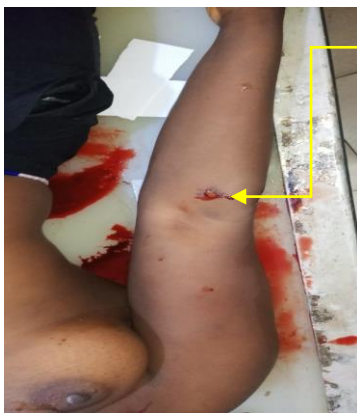- 4.** Charloe also suffered other painful stabbed wounds which appeared to be superficial and not life-threatening per se, though a FORENSIC EXAMINATION by a trained individual was warranted to make such a determination as the autopsy was done 1-month after her murder.



Stab wounds (**#s 3, 4 & 5**). These 3 stab wounds to the chest appears to be superficial.



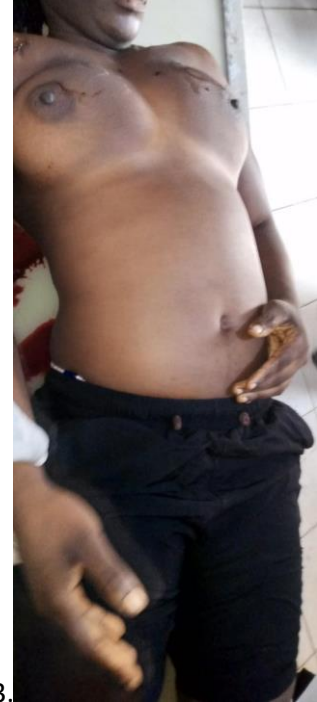
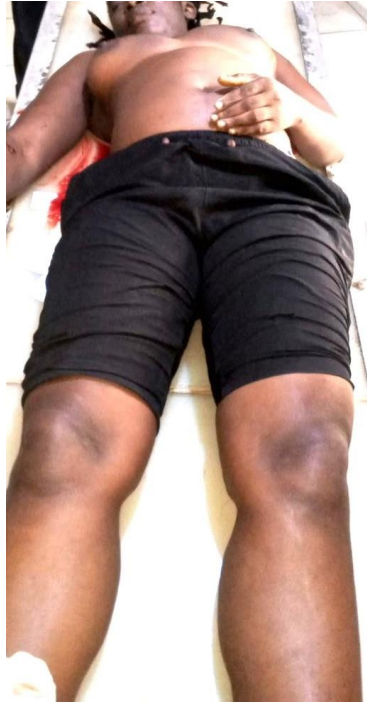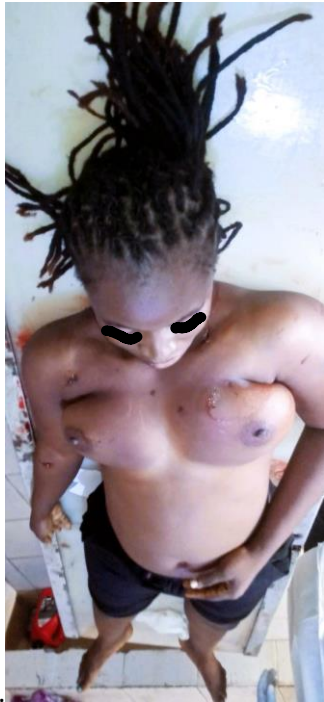Stab wound (**#s 6 & 7**) to her upper left shoulder(superficial) and left arm (was deeper and was **sutured** at the hospital or prior).



Stab wound (**#8**) to the right forearm. The wound appeared superficial and based on the anatomical location could be considered a non-life threatening as well.

**5.** Looking below at Charloe’s body, it is very interesting to note the following:

- A.** There are no stab wounds involving the stomach area (abdomen) or from the waistline and below to her feet.
- B.** No “defensive” wounds (cuts or stabs) were present on her arm and hands.



**6.** Given the information provided above, it is fair to raise the following arguments:

- A.** Charloe was more than likely incapacitated and could not defend herself as she was being stabbed. This can be attributed to several possibilities, namely:
  - (i) She may have been overpowered in a scuffle and then stabbed or stabbed while in a fight.
  - (ii) She lost a lot of blood after being stabbed in her neck and other vital areas previously discussed and could not defend herself either.



B. Charloe was probably unconscious after receiving a fatal stab wound. To cover up and create the perception of an “intruder”, other stab wounds were made, which is why several of these wounds are superficial and not deep penetrations.

C. If she was stabbed by an intruder:

1. Why were there no injuries on her abdomen or below?
2. Why were there no “defensive” wounds noted on her hands and arms?
3. Why would an intruder spend so much time inflicting “**selective**” injuries on an individual who was **NOT** the only occupant in the home as she would have been subjected to yelling, therefore alarming the others?

### A Selective Overview and Analysis of the Crime Scene:

A. Unspecified blood-stained sections of the residence which clearly indicate movement of a seriously injured person be it by oneself or being carried by another or others.



1.



2.



3.

B. Blood-stained foot and shoe prints in what appears to be a “**hallway**” section of the home. This was contributed by the movement of individuals who were occupants of the residence and those who entered the home to “rescue the family from the arm robbers”.

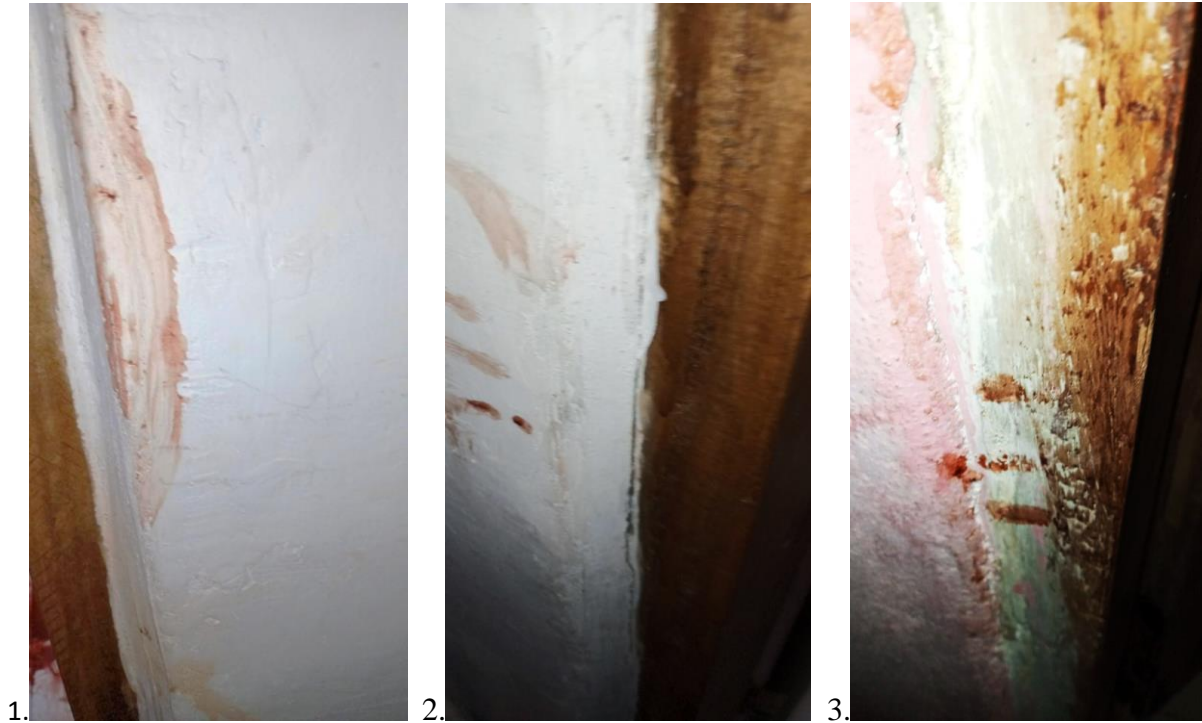


1.



2.

- C. Blood-stained pattern on the entrance of the doorway to the bathroom where the body of Charloe Musu was carried. These stains and fingerprints were made by a person(s) who had physical contact either with a person who was bleeding severely or may have suffered an injury as well.



- D. Blood-stained section of the bathroom which indicates the presence of heavy blood disbursement and an attempt to destroy evidence by “washing the blood away” not only from the scene but also from the “contributor” as in the deceased (Charloe Musu) or from the “carrier”. Remember, as mentioned in the early parts of this story, **Mr. Alvin Gezzie**, an eyewitness to the scene, had stated that “Charloe was stabbed to death” in the bathroom. This means that we can place Charloe’s body in the bathroom at some point in time. The photos in this section show diluted blood on the floor-pic 1, a bloody bathtub which can be seen through what appears to be a mirror on the wall-pic 2, the blood stains on the base and the aluminum frame of the bathroom window are from a person with blood hands, raising and resting their hand on the base of the window, with some blood being spattered on the tile-pic 3.



1.



2.



3.



4.

## Conclusion

Given the facts presented in this case, it is fair to say that a full-scale forensic investigation was and is warranted to resolve this case and draw a logical conclusion. After watching the Liberian National Police's MICAT press conference dated June 21, 2023; it is now vividly clear that in addition to the "preliminary" autopsy report being a "non-reliable" evidentiary material as it contradicts the fatal injuries sustained by the late Charloe Musu and cannot be supported by crime scene findings in regards to the blood-stained patterns; detailed forensic elements were also not proffered so as to support the arrest and prosecution of defendants *Gloria Musu-Scott* (Former Chief Justice, R.L.), *Gertrude Newton*, *Alice Johnson*, and *Youdeh Wisner* apart from the fact that they were simply occupants of the residence at the time of Charloe's death. As the charges faced by these individuals include *murder*, *criminal conspiracy*, and the *provision of false statement*, I urge the Ministry of Justice to secure the services of forensic professionals to ensure that a "threshold" is met to establish a *Prima facie* in this case as a means of securing both a speedy trial and conviction. However, it is also advised that the defense counsel analyzes the probative value of the forensic facts in this case as it prepares for a potential trial to come.



References:

1. [https://www.facebook.com/watch/live/?extid=WA-UNK-UNK-UNK-AN\\_GK0T-GK1C&mibextid=MO6U97&ref=watch\\_permalink&v=1171742270174629](https://www.facebook.com/watch/live/?extid=WA-UNK-UNK-UNK-AN_GK0T-GK1C&mibextid=MO6U97&ref=watch_permalink&v=1171742270174629)
2. <https://frontpageafricaonline.com/news/liberia-cllr-gloria-musu-scott-questions-the-motive-of-her-attempted-assassination-as-she-mourns-her-daughter-who-got-killed-in-the-mayhem/>
3. [https://reference.jrank.org/fitness/Cardiovascular\\_System.html](https://reference.jrank.org/fitness/Cardiovascular_System.html)
4. <https://independentprobe.com/2023/03/21/pathologist-kolee-announces-provisional-cause-of-death-of-charloe-musu/>
5. [‘Highly nonsensical’ - Liberia news The New Dawn Liberia, premier resource for latest news](#)
6. [Forensic Death Investigator, Dr. Rockefeller Cooper, Bores Holes in Specialist Pathologist, Dr. Benedict Kolee’s, ‘Preliminary Autopsy Findings’ - Independent Probe Newspaper](#)
7. [https://www.facebook.com/watch/live/?ref=watch\\_permalink&v=3492369100978101](https://www.facebook.com/watch/live/?ref=watch_permalink&v=3492369100978101)